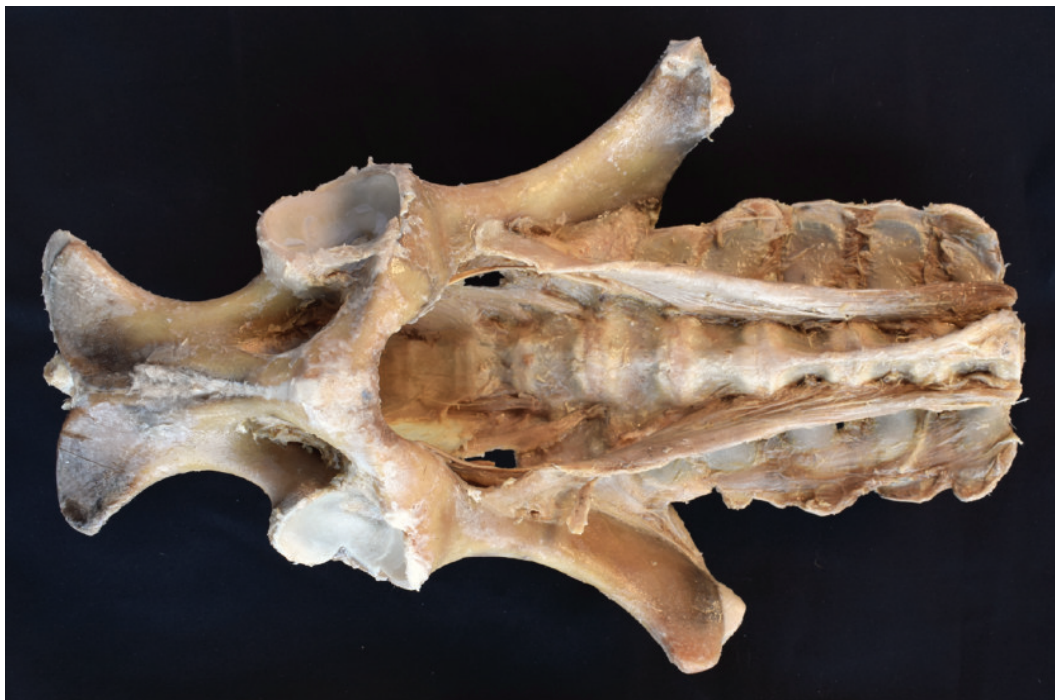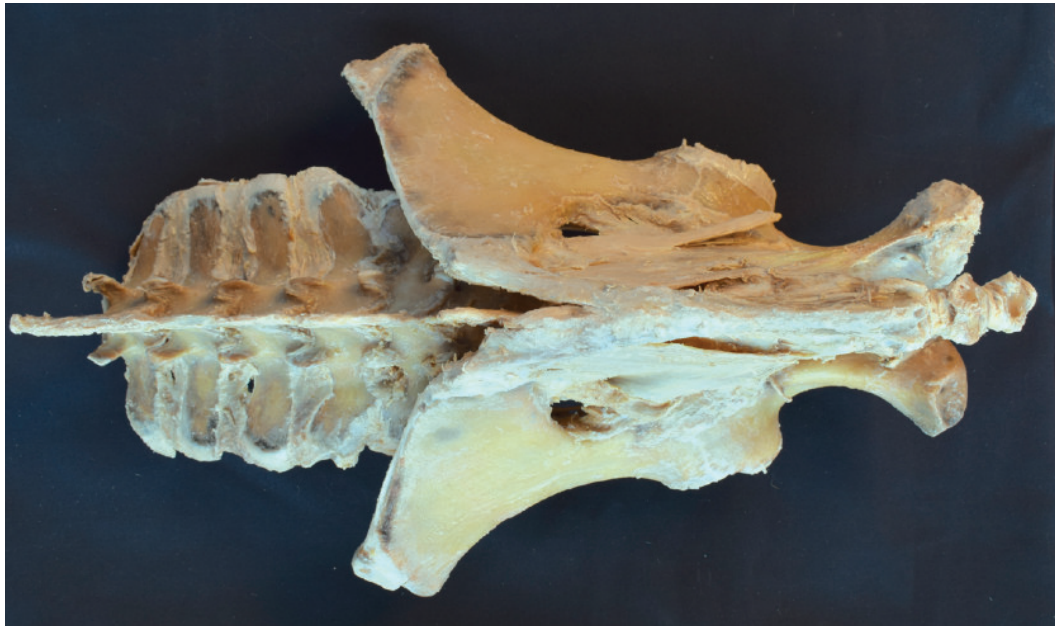


**VP10020 Horse (foal) pelvis dissection - ligaments****VP10020 Horse (foal) pelvis dissection - ligaments**

This specimen is focused on the sacroiliac joint, the two coxal bones (os coxae) are exposed in the dissection: Ilium, pubis and ischium, together with lumbar vertebrae and sacrum. At the sacroiliac joint, the dorsal sacroiliac ligament can be identified. The broad sacrotuberous ligament of the pelvis extends from the lateral sacral crest to the sciatic spine and ischial tuberosity. The greater sciatic foramen occupied by the lumbosacral trunk. From the vertebral bodies and part of the transverse processes of the lumbar vertebrae, the tendons of insertion of the psoas minor muscles are identified. The ventral longitudinal ligament connects the ventral aspect of most cranial lumbar vertebral bodies.